

Chair and Department of Neurology, Chair and Department of Interventional Radiology
and Neuroradiology, Medical University of Lublin
Department of Diagnostic Imaging, Central Railway Hospital, Warsaw

ANNA JAMROZ-WIŚNIEWSKA, TERESA MARCZAK,
MARZENA JANCZAREK,
MONIKA BEKIESIŃSKA-FIGATOWSKA, ZBIGNIEW STELMASIAK

*Diagnostic difficulties in multiple enhancing ring lesions
in neuroimaging: report on a case of neurocysticercosis
in Central Europe (Poland) presenting as hemiparesis*

Neurocysticercosis is the most frequent parasitic disease of the central nervous system, although it is mainly a problem in developing countries. It reaches an incidence of 3.6% in Central and South America, sub-Saharan Africa and in some regions of the Far East. It is rare in Eastern and Central Europe including Poland. Neurocysticercosis is caused by cysticercus, i.e. encysted larval form of the pork tapeworm *Taenia solium*. Humans acquire neurocysticercosis by ingesting food or water contaminated by eggs of *T. solium* shed in feces of human carriers, or by fecal oral autoinfection, unnaturally replacing pigs as the intermediate host of the parasite.

Humans are the definitive host of *T. solium* (they carry the intestinal tapeworm). A pig is the normal intermediate host carrying larvae or cysticerci. Humans ingest cysticerci through poorly cooked infected pork. Cysts evaginate in the small intestine and develop adult form excreting fertile eggs. When pigs or humans ingest stool or food contaminated with *Taenia* eggs, the embryos actively cross the intestinal wall, get into the bloodstream, and are transported to most tissues, where they reside as cysticerci – they are found most commonly in the central nervous system, but can be also located in the eye, muscle, liver or subcutaneously.

Due to variable localisation and the different number of parasites, patients may present with different symptoms or may even be asymptomatic. The most common manifestation of neurocysticercosis is epilepsy. Besides, patients present with headache, intracranial hypertension, strokes (ischaemic stroke or haemorrhage), neuropsychiatric disturbances, diplopia, and hydrocephalus. Other rare forms of neurocysticercosis are also possible, such as intrasellar neurocysticercosis (causing endocrinologic disturbances), spinal neurocysticercosis (spinal dysfunction), ocular neurocysticercosis (e.g. monocular blindness) (1, 2).

CASE REPORT

A 55-year-old female, J.J., farmer, widow living with a 15-year-old daughter, was admitted from the second reference neurological department in order to continue the diagnostic procedures. Until February 2004 she had been a relatively healthy person – she was mildly hypertensive, but not diabetic, she was a non-smoker. In the past she was treated unsuccessfully because of ascariasis and vermiculosis

(from early childhood). She admitted that she had often eaten raw meat from the local market. On 20 February 2004 she presented acute onset left side weakness and speech disorder. Neurological examination revealed a conscious individual with slight dysarthria. Motor system showed left side hemiparesis with grade 3/5 power. Deep tendon reflexes were brisk on the left side with pyramidal symptoms. Sensory system examination was disturbed on the left side. There were no cerebellar signs. Contrast enhanced computerised tomography (CT) revealed non-specific oedema of the right hemisphere. Simultaneously made contrast enhanced magnetic resonance imaging (MRI) revealed multiple small enhancing ring lesions (Fig. 1). Radiologists suggested differential diagnosis among brain abscesses, metastatic lesions and acute multiple sclerosis lesions. Neurocysticercosis was also

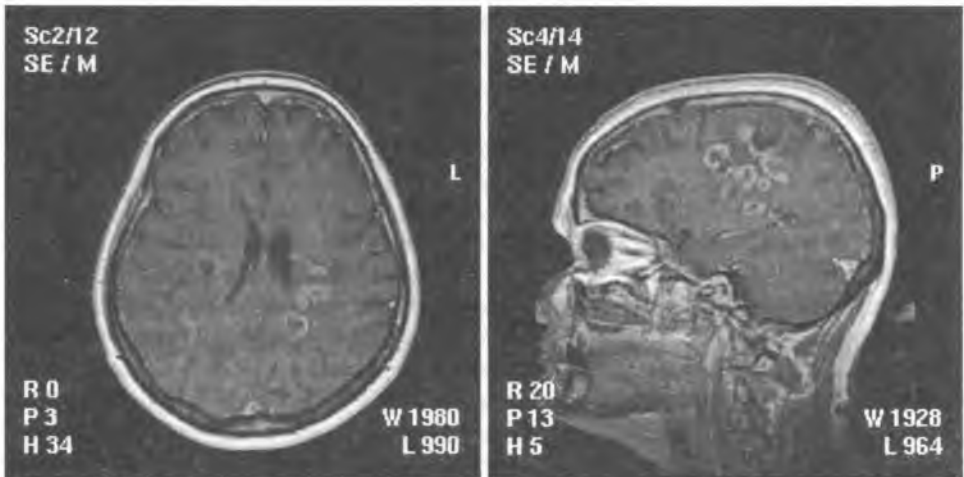


Fig. 1. Contrast enhanced magnetic resonance imaging (MRI) revealing multiple small enhancing ring lesions before treatment (made at the Department of Diagnostic Imaging, Central Railway Hospital, Warsaw)

suggested. However, enzyme-linked immunoelectrotransfer blot assay in serum showed a negative result. Infection with Human Immunodeficiency Virus, *Echinococcus granulosus* and *Toxoplasma gondi* was excluded. Microscopic examination of three stool samples revealed eggs of *Ascaris lumbricoides*, but neither ova nor proglottides of *T. solium* were found. There was neither peripheral leukocytosis (the white blood cell count 5630) nor eosinophilia (4%). Cerebrospinal fluid analysis showed normal cytosis (1/μl) and glucose level (66mg%) and elevated protein levels (167mg%). A soft-tissue radiograph did not reveal any calcifications in thigh musculature. Nevertheless, regarding the patient's history of parasitic diseases and typical of neurocysticercosis MRI findings (3), the diagnosis was made. The patient was treated with anticysticercal drug, albendazole, in doses 1000 mg per day for 28 days, with the concomitant use of steroids (4). The patient showed clinical improvement in her hemiparesis. Follow-up MRI revealed disappearance of previously described lesions; instead, it showed multiple demyelinating lesions without enhancement with contrast (Fig. 2). Two weeks after treatment the patient's neurological status was stable; she suffered from mild anxiety disorder. Half a year later the patient's neurological status stayed the same.

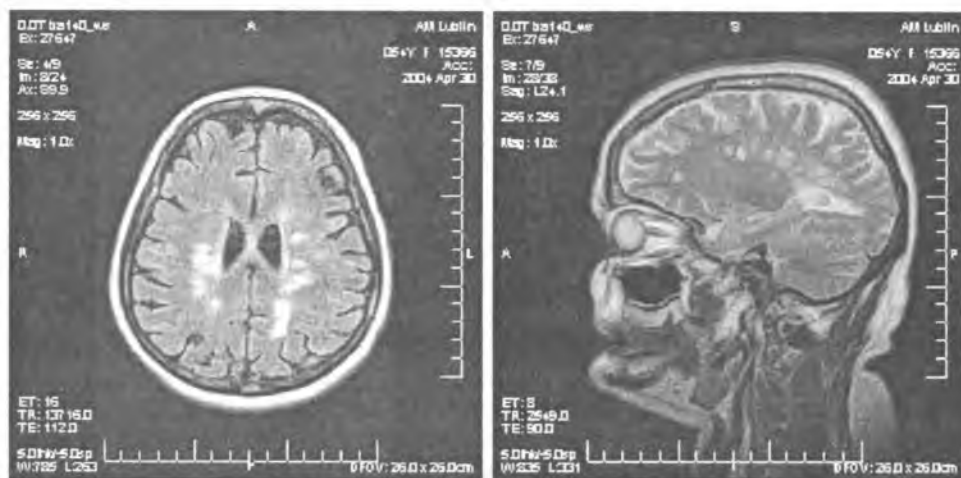


Fig. 2. Follow-up MRI revealing multiple demyelinating lesions without enhancement with contrast (made at the Department of Interventional Radiology and Neuroradiology, Skubiszewski Medical University, Lublin)

DISCUSSION

Neurocysticercosis is a rare disease in Central Europe. It usually manifests as epilepsy. In our case MRI scan of multiple enhancing ring lesions was atypical of hemiparesis caused by ischemic stroke. It revealed characteristic neurocysticercosis lesions. The clinical and radiological improvement with anticycercal treatment concomitant with steroids also supports the diagnosis. Apart from other problems such as brain abscesses, cerebral amebiasis, metastatic lesions, CNS toxoplasmosis, CNS cryptococcosis and tuberculosis of the CNS, neurocysticercosis should also be considered as a possible cause of described radiological changes (1, 2, 5).

REFERENCES

1. Carpio A.: Neurocysticercosis: an update. *Lancet Infect Dis*, 2, 751, 2002.
2. Gonzalez A. E. et al.: Control of *Taenia solium*. *Acta Trop.*, 87, 103, 2003.
3. García H. H., Del Brutto O. H.: Imaging findings in neurocysticercosis. *Acta Trop.*, 87, 71, 2003.
4. Kalra V., Dua T., Kumar V.: Efficacy of albendazole and short-course dexamethasone treatment in children with 1 or 2 ring-enhancing lesions of neurocysticercosis: a randomized controlled trial. *J. Pediatr.*, 143, 111, 2003.
5. Krajewski R., Stelmasiak Z.: Cerebral hydatid cysts in children. *Childs Nerv. Syst.*, 7, 154, 1991.

SUMMARY

This case reports a rare in Poland, non-epileptic manifestation of neurocysticercosis where a 55-year-old female presented with acute onset left hemiparesis. Computerised tomography revealed a non-specific oedema of brain and magnetic resonance imaging showed multiple small enhancing lesions.

In the past the patient was treated without success because of ascariasis and vermiculosis. The patient improved after treatment with mannitol, albendazole and steroids. The follow-up magnetic resonance imaging revealed non-unifocal and non-enhancing demyelinating lesions. Apart from other problems such as brain abscesses, cerebral amebiasis, metastatic lesions, CNS toxoplasmosis, CNS cryptococcosis and tuberculosis of the CNS, neurocysticercosis should also be considered as a possible cause of described radiological changes.

Problemy diagnostyczne w przypadku obecności wieloogniskowych zmian pierścieniowatych w badaniu rezonansu magnetycznego głowy: opis przypadku wężrzycy mózgu w Polsce manifestujący się pod postacią niedowładu połowicznego

Opisujemy przypadek rzadkiej w Polsce, niedrgawkowej manifestacji wężrzycy mózgu u 55-letniej pacjentki, u której nagle wystąpił niedowład lewych kończyn. W badaniu tomografii komputerowej mózgu uwidoczniło niespecyficzny obrzęk, a w badaniu rezonansu magnetycznego głowy stwierdzono obecność licznych ognisk torbielowatych ulegających silnemu obrączkowatemu wzmocnieniu kontrastowemu. Ze względu na dodatni wywiad w kierunku chorób odzwierzęcych wysunięto podejrzenie wężrzycy mózgu. Po leczeniu mannitolem, albendazolem i glikokortykosteroidami wystąpiła poprawa w stanie neurologicznym pacjentki. Kontrolne badanie MRI głowy ujawniło obecność mnogich ognisk hiperintensywnych w obrazach T2-zależnych i FLAIR, nieulegających wzmocnieniu po podaniu środka kontrastowego. Wnioski: Obraz wieloogniskowych zmian pierścieniowatych wzmacniających się po podaniu środka cieniującego należy różnicować pomiędzy ropniem mózgu, zmianami przerzutowymi, zmianami typowymi dla ostrej fazy stwardnienia rozsianego, gruźlicy, toksoplazmozy mózgu, amebiazy czy kryptokokozy OUN. Nie można jednak wykluczyć wężrzycy mózgu, która chociaż jest chorobą dosyć rzadką w Europie Środkowej, może wystąpić u osób narażonych na zarażenie jajami tasiemca uzbrojonego (*Taenia solium*).