

Department of Prosthetic Dentistry, Medical University of Lublin

MICHAŁ IWANEK, JANUSZ BOROWICZ, ANDRZEJ BOŻYK,
MAGDALENA BAKALCZUK, JANUSZ KLEINROK

*Iatrogenic pain dysfunction syndrome
of masticatory system – case study*

Iatrogenic pain dysfunction syndrome after prosthetic treatment is a problem which is poorly examined and unwillingly brought up in medical papers. Its causes and methods of treatment are still analyzed (1,2). In most cases it is connected with TMJ disc displacement, which explains the appearance of acute pain symptoms and difficulties in treatment (3). That is why authors believe that a description of this case and its treatment should be helpful in future studies on this syndrome.

CASE DESCRIPTION

A female patient, age 71, came to The Department of Prosthetic Dentistry University School of Medicine in Lublin because of constant pain of the face which was radiating in the direction of temple and neck. Strength of the pain was defined as 6–7 in ten degrees of VAS scale. In history the connection between pain manifestation and making prosthetic restoration about four years ago was ascertained. The patient described her psychonervous condition

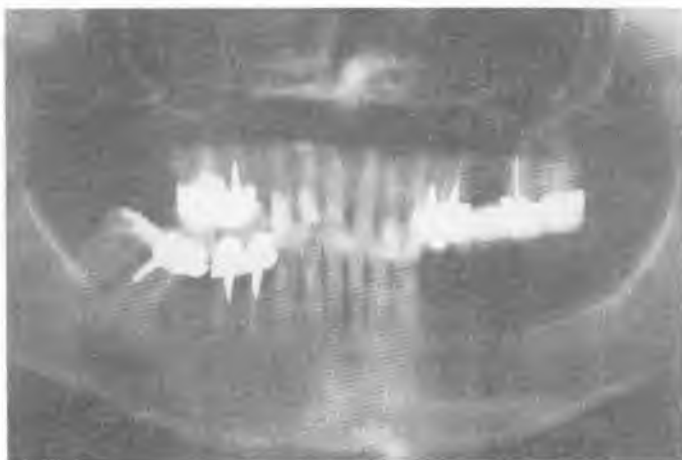

Fig.1. Panoramic radiographs made during the first visit




Fig.2. Alveolar lack in mandibula

as “excessively excitable”; she also admitted that she habitually clenches and grinds her teeth. After clinical examination extensive prosthetic restorations were found such as bridge 18, 17, 15, 14 and porcelain veneered crowns 25, 26, 35, 36 and big alveolar lack on the right side of lower jaw (Fig.1, 2). Restorations were performed in diminished height of occlusion, in unsettled plane of intercuspitation (Fig.3). Hard teeth attrition 32, 33, 42 was also examined. The history was ascertained that the patient also used lower removable partial denture, but after a short time it was damaged. The analysis of mandibular movements showed: opening – 45mm, with sinuous deviation during mandibular opening, protrusion 5 mm with deviation 3 mm to the right, movement to the right 8mm, to the left 10mm. Basing on clinical examination iatrogenic pain dysfunction syndrome with TMJ disc displacement with block on the left side was stated. On the basis of tests according to Kleinrok therapeutic position of mandibula in increased occlusion level did not involve protrusion of lower jaw (Fig.4). Roentgenograms of temporal-mandibular joints in this position showed bilateral central position of lower jaw’s caput and lightly narrowed articulatory slit (Fig.6). Bilateral flattening of posterior facies of lower jaw’s heads showed practiced parafunction for many years (clenching, gnashing). Circadian repositioning splint was used with canine guidance during lateral movements and incisors guidance during protrusion. The patient said that parafunctions are very harmful, and she needed to control herself and to think positively in order to fight her stress. The patient had a check-up examination every 2–5 weeks until the compensation of the changing splint occlusion. Thanks to these procedures splint height was corrected gradually and mandibular protrusion was possible. After 12 months regression of pain was complete and the model of mandibular movements was also improved: opening – 45 mm without deviation, protrusion 6 mm without deviation, movement to the right 12, to the left 11mm. After the next 9 months of

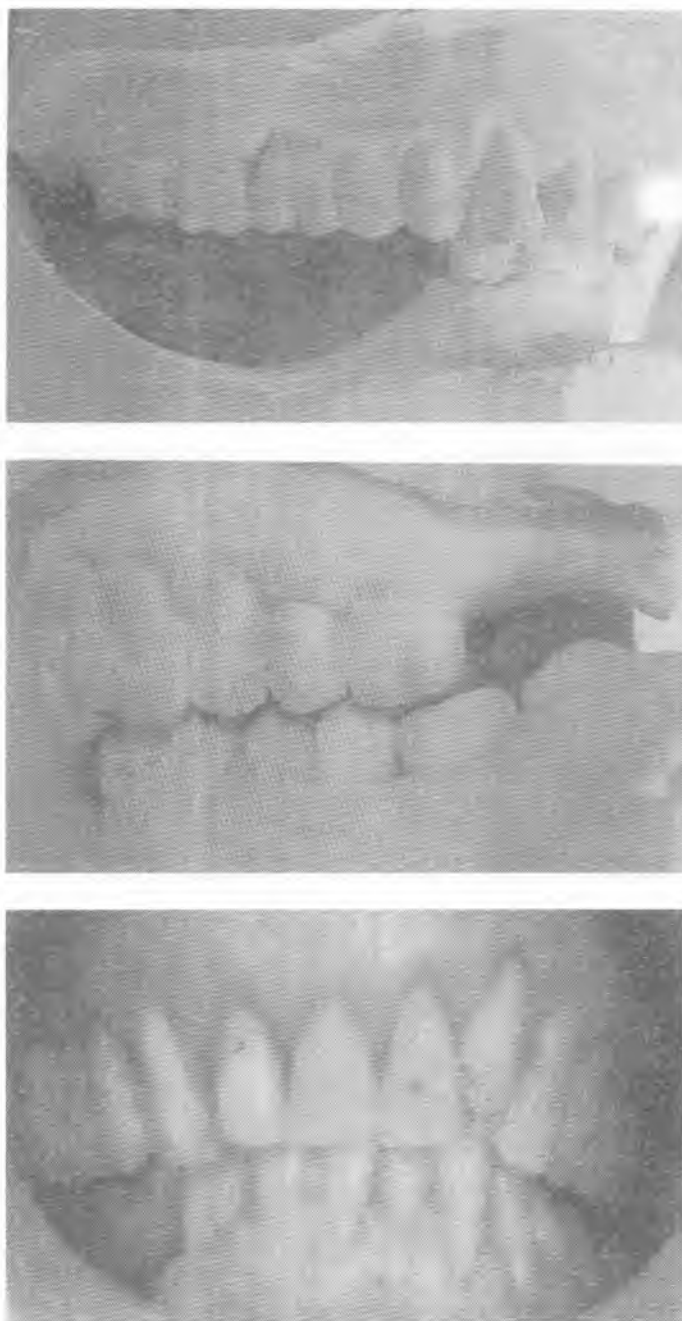

Fig. 3. Maximal intercuspitation before treatment (diminished height of occlusion)

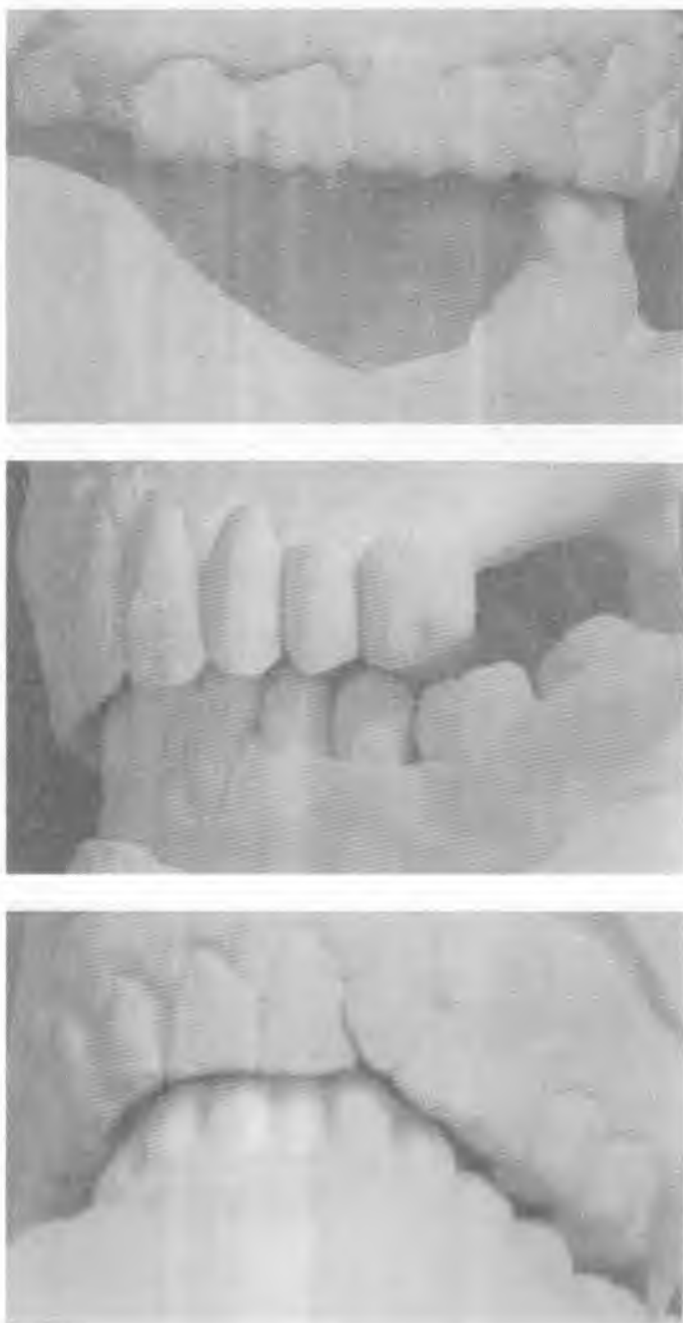

Fig. 4. Therapeutic position of lower jaw

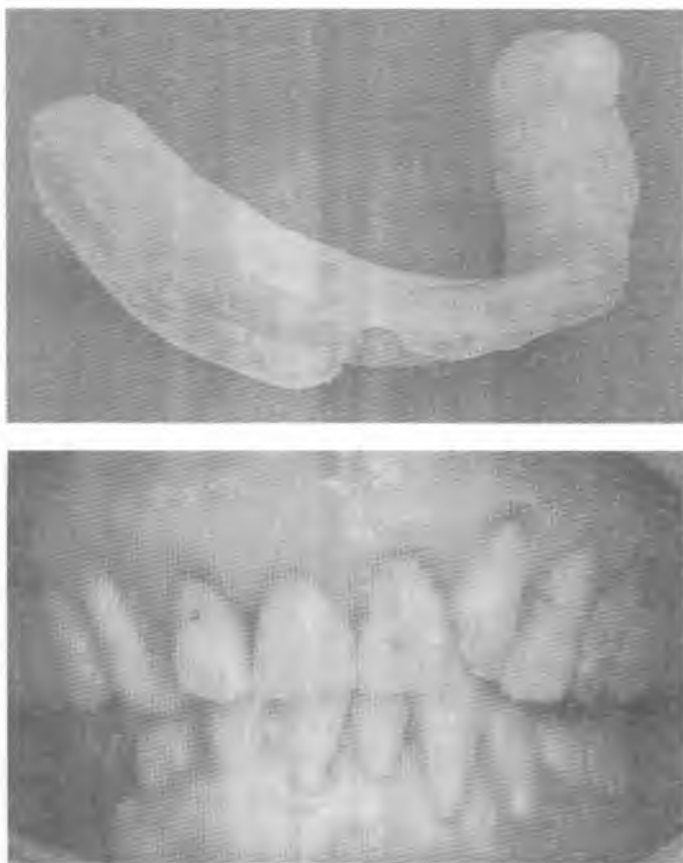


Fig. 5. Acrylic repositioning occlusal splint

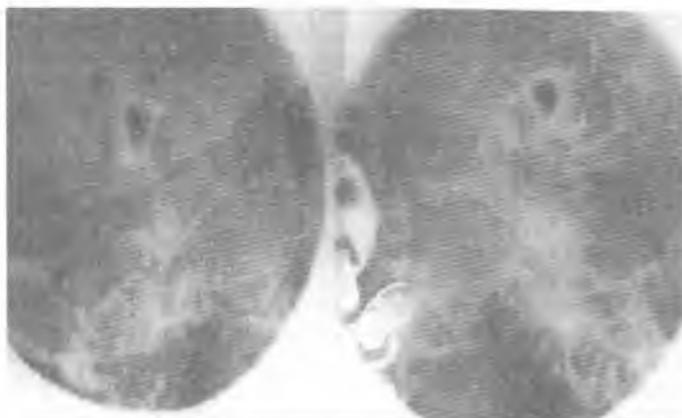

Fig. 6. TMJ X-ray take in therapeutic position

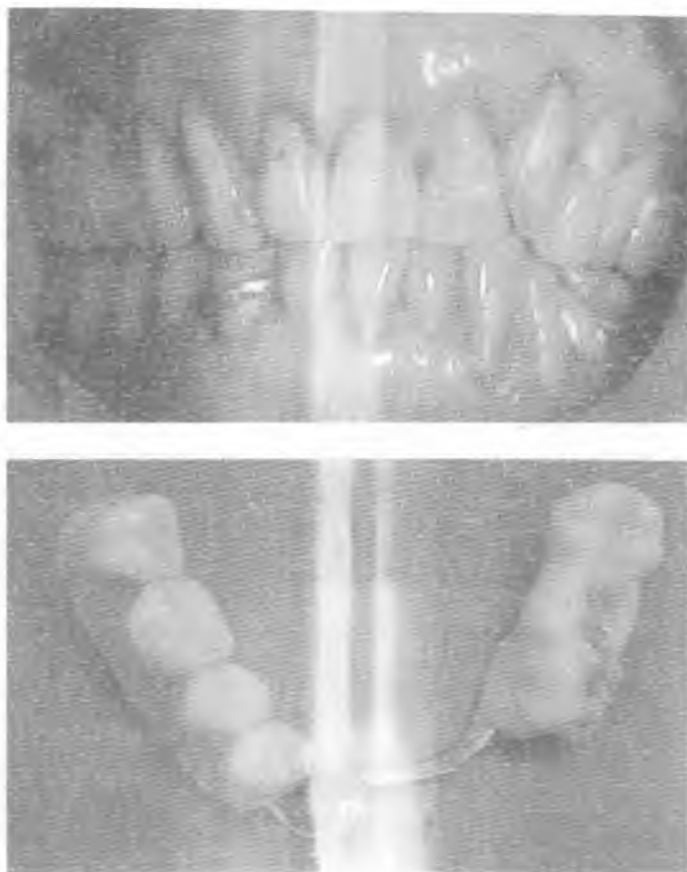

Fig. 7. Removable partial overdenture (d. 34–37)

using splint it was proved that mandibula was in stable position according to maxilla, that is why the final prosthetic restoration was made. In fixed therapeutic position of lower jaw occlusion plane was compensated by grinding of overhanging cuspids of tooth crown 25,26 and making removable partial overdentures of teeth 34,35,36,37 with acrylic surface. that is why probable occlusion correction was possible (Fig.7). Pathologous attrition of teeth 32,33,34 was corrected using composite material.

DISCUSSION

Lack of pain symptoms of masticatory system before prosthetic treatment testifies to iatrogenic activity of the prosthesis. An error at the stage of establishing the occlusion height probably caused later intra-articular disorder: lower jaw heads displacement to the back, articular slit narrowing and pushing discs from their physiologic position (4). Occlusional parafunctions made by the patient and later alveolar lack of lower jaw were additional factors that burdened temporal-mandibular junction. Because of lack of data about the function of masticatory system before prosthetic therapy we can not diagnose if the performed therapy was

the direct cause of discs displacement, or if these intra-articular disorders existed earlier in the adjusted form (3,5).

CONCLUSIONS

1. This case shows that occlusional splint used in the treatment of pain dysfunction syndrome of masticatory system gives positive results.

2. In order to avoid complications after prosthetic therapy an analysis of masticatory system function should be performed: analysis and measurement of mandibula free movement, of accoustic symptoms of temporal-mandibular junction, of pain during lower jaw movement and other pains in head and neck, ophthalmic and auricular symptoms, and also occlusion analysis.

REFERENCES

1. Akł A. et al.: The frequency of various types of disc displacement and its relation to occlusion. *Acta Stomatol. Belg.*, 6, 53, 1996.
2. Foucort J. M. et al.: MR of 732 TMJs: anterior, rotational, partial and sideways displacements. *Eur. J. Radiol.*, 28, 1, 86, 1998.
3. Kleinrok M.: Zaburzenia czynnościowe układu ruchowego narządu żucia. Sanmedia, wyd.IV, Warszawa 1992.
4. Kleinrok J. Kleinrok M.: Jatrogeny bólowy zespół dysfunkcji narz. żucia po leczeniu protezami stałymi. *Prot. Stom.*, LI, 5, 2001.
5. Koeck B., Utz K. H.: Rekonstrukcje protetyczne. In: B. Koeck: Zaburzenia czynnościowe narządu żucia. Urban/Partner, 283, Wrocław 1997

SUMMARY

A female patient, age 71, came to The Department of Prosthetic Dentistry University School of Medicine in Lublin with pain dysfunction syndrome after treatment by extensive prosthesis of upper and lower dental arches. After examination many abnormalities of prosthetic restorations were ascertained. After 21 months of repositioning occlusal splint treatment the symptoms of pain dysfunction were gone, which permitted final prosthetic restoration. This case proves that using repositioning occlusal splint should be the first choice procedure in the treatment of iatrogenic pain after prosthetic treatment.

Jatrogeny bólowy zespół dysfunkcji narządu żucia – opis przypadku

Chora, lat 71, zgłosiła się do Zakładu Protetyki AM w Lublinie z ostrym zespołem dysfunkcji narządu żucia po leczeniu rozległymi protezami, obejmującymi górny i dolny łuk zębowy. Badaniem klinicznym stwierdzono liczne nieprawidłowości wykonanych uzupełnień protetycznych. Po 21 miesiącach leczenia repozycyjną szyną zgryzową ustąpiły objawy dysfunkcji narządu żucia, co pozwoliło na wykonanie ostatecznych uzupełnień protetycznych. Przedstawiony przypadek dowodzi, że zastosowanie szyny zgryzowej powinno być postępowaniem z wyboru w leczeniu jatrogenego bólu po leczeniu protetycznym.