

2nd Department of Radiology, Medical University of Lublin  
Department of Dental and Maxillofacial Radiology, Medical University of Lublin  
Experimental Teratology Unit of the Human Anatomy Department  
Medical University of Lublin

INGRID RÓŻYŁO-KALINOWSKA, ANNA MICHALSKA,  
FRANCISZEK BURDAN

*Optimization of analysis of skeletal ossification of laboratory animals by means of digital radiography software options*

Quantitative analysis of skeletal ossification is of extreme importance in teratological studies. Presently it is mainly conducted by the means of analysis of stained fetal bones (1,5). However, a novel application of digital radiography system for the purpose of such studies has recently been introduced (2). Digital radiography software enables image manipulation and reformatting, thus allowing precise diagnosis and measurements even in cases when exposure parameters are suboptimum and visualised structures are faintly radiopaque.

The aim of the paper is evaluation of digital radiography software options in optimisation of analysis of skeletal ossification in rats.

MATERIAL AND METHODS

Wistar rat pups at the age 0 to 22 days of postnatal life were examined. Every pup was radiographed by means of Planmeca Intra intraoral X-ray machine (Planmeca, Finland), operating at 70 kVp, and Digora (Soredex-Orion Company, Finland) digital radiography system using a multiple use storage phosphor (photostimulable) image receptor wrapped in a plastic envelope. Several radiograms of each pup were obtained depending on the size of the animal as the imaging plate size (30x40mm) in many cases did not overpass the dimensions of the radiographed animal. Each examined pup was positioned in prone, supine and right lateral recumbent positions in the centre of the plate with the central X-ray beam perpendicular to the plate. A fine layer of distillate water was used to fix the animal on the plate envelope. All obtained images were stored in hard disk archives as graphic files (bitmaps), and subsequently evaluated by two independent observers (IRK and FB). There were carried out linear measurements (width and thickness) of lumbar vertebra as well as density measurements of vertebral ossification (maximum and mean values of optical density). In order to optimize viewing conditions as well as density and linear measurements there were used and evaluated all available image reformatting options and filters of digital radiography software Digora 2.0.

## RESULTS

Digital radiography software proved useful in optimization of viewing conditions that in turn reflected quality and reproducibility of linear and density measurements. Correct linear and density measurements were possible only after calibration of each image using Image Resolution Calibration method. Afterwards, every radiogram was magnified; two-fold magnification factor was used (Figs. 1. A, B). Larger magnification resulted in visualisation of

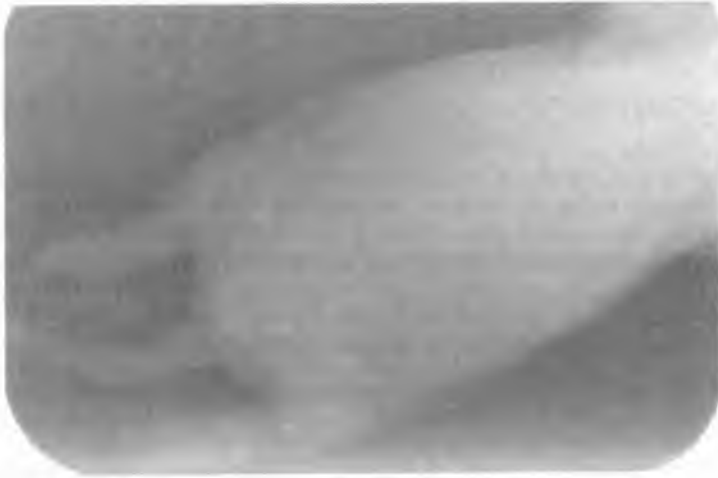

Fig. 1A. Native digital radiogram of a 1-day old rat pup




Fig. 1B. Two-fold image magnification of the same image results in better delineation of poorly ossified lumbar vertebra

individual picture elements (pixels) that deteriorated viewing conditions. The most often used function was manual change of image contrast and brightness. Automatic Grayscale Adjustment

and automatic Enhancement option proved inappropriate in this study for evaluation of rat pups bone ossification. In some cases manual adjustment of contrast and brightness was applied simultaneously with the positive mode which was advantageous in younger and smaller pups (Fig. 1 B). In contrast, 3D Emboss function was more suitable for visualization of bone edges in older animals with a more advanced process of ossification (Fig. 2.A, B). It was also used in combination with positive image reformatting. Activation of single colour highlight of pixels characterized by the same density (tomosynthesis) helped in precise determination of bone margins during linear and density measurements. Full colour option proved advantageous neither in carrying out of linear nor density measurements.



Fig. 2A. Native digital radiogram of lumbar spine of a 22-day-old rat pup



Fig. 2B. The same image reformatted using 3D Emboss function and positive mode allows better visualization of bone edges of lumbar vertebra

## DISCUSSION

Evaluation of skeletal development is a widely used technique in *in vivo* studies. Nowadays, skeletal ossification of laboratory animals is routinely evaluated by staining of fetal bone (alizarin red-S single-staining) and less frequently, by staining of both bone and cartilage (double-staining with alcian blue). Both methods are relatively simple, fast, and inexpensive, but they are mostly qualitative and subjective (1,5). In teratologic studies the methods which allow quantitative analysis are preferred over qualitative indices. Therefore, recently there has been proposed a novel use of digital radiography for the assessment of skeletal ossification, which can be supplementarily used in routine teratologic studies (2).

Digital radiography is actually based on the same properties of X-ray attenuation by body tissues as conventional radiography. However, the two techniques differ in image receptors. While conventional radiography uses a film, digital image receptors are based either on CCD (charge coupled device) or PSP (photostimulable phosphor) technologies. The Digora system is equipped with storage (photostimulable) phosphor multiple-use imaging plates. After exposition to X-rays, latent image is formed in the plate by stored electrons. Stimulation of the plate with a laser beam of specific wavelength causes emission of short-wavelength light that has an intensity proportional to the amount of X-rays stored by the phosphor. The emitted light is detected by a photomultiplier tube and digitized to appear as the image presented on the computer screen in the form of a grey scale (6,9). To every pixel a value in the range from 0 to 255 is assigned. Zero corresponds to areas where no attenuation of X-rays occurred and such areas are presented on the monitor as black. Pixels with the highest value (255) are presented as white and correspond to areas in which the ionising radiation has been completely absorbed. The values between 1 and 254 are presented as different levels of grey on the monitor and are proportional to the amount of absorbed ionising radiation (8). The brightness and contrast (presence of perceptible differences of brightness between adjoining areas) of the image influence viewing conditions and diagnosis (4,6,11).

The discussed digital radiography system is equipped with the possibility of linear (distance) and density measurements, that is calculation of pixel values along a chosen line or within a selected region of interest, after initial image calibration. With the Density Measurements window of the software, minimum, maximum and average values of the density within a selected area or along a drawn line are given. As the location of the starting and ending point of the line is known, reproducibility of the results is possible. However, viewing conditions are an additional factor influencing accuracy and reproducibility of measurements (3,4,6,7,10,11). It is especially true in cases of rat pups used in this study.

Laboratory animals fetuses and pups are small, their bone ossification is incomplete therefore tissue contrast is poor and evaluation of their native radiological images is challenging. Owing to the possibilities of digital radiography software, image enhancement and reformatting can be achieved (4,7,10). It is possible to regulate such image parameters as contrast and brightness, which makes even an initially imperfect image valuable for diagnosis (11). Further advantages of digital enhancement of X-ray images are the possibility of their presentation not only as static negative images, but in different options of software such as positive mode, single color highlight (tomosynthesis), full color presentation and 3D-Emboss (pseudo-three-dimensional image). However, one of the most useful functions was image magnification, especially in cases of younger and smaller animals with poorly ossified bones. Nevertheless, only two-fold magnification factor was routinely used as further enlargement of the digital image resulted in visualisation of individual pixels that impeded measurements as human eye tends to discern geometrical structures within viewed images.

Manual adjustment of brightness and contrast proved more valuable in this specific experiment setting than Automatic Grayscale Adjustment and automatic Enhancement options, which are designed for dental studies. Size and age of the examined animals influenced the choice of image enhancement tools: manual adjustment of contrast and brightness of positive

images proved advantageous in younger and smaller pups, while in older and bigger animals it was the 3D Emboss function that helped in visualization of bone edges. Full colour option proved valuable neither in cases of linear nor density measurements, while introduction of single colour highlight (tomosynthesis) significantly aided in precise determination of bone margins before carrying out of linear and density measurements.

In conclusion, digital radiography is a novel and precise tool in determination of skeleton ossification and could be used as a supplement to routine staining methods. Moreover, application of digital radiography image enhancement options optimizes and improves viewing conditions as well as allows higher accuracy and reproducibility of the measurements.

#### REFERENCES

1. Burdan F.: Intrauterine growth retardation and lack of teratogenic effects of prenatal exposure to the combination of paracetamol and caffeine in Wistar rats. *Reprod Toxicol.*, 17, 51, 2003.
2. Burdan F. et al.: A new, rapid radiological procedure for routine teratological use in bone ossification assessment: a supplement for staining methods. *Teratol.*, 66, 315, 2002.
3. Dove S., McDavid W.: A comparison of conventional intraoral radiography and computer imaging techniques for the detection of proximal surface dental caries. *Dentomaxillofacial Radiol.*, 21, 127, 1992.
4. Gotfredsen E. et al.: Observers' use of image enhancement in assessing caries in radiographs taken by four intra-oral digital systems. *Dentomaxillofac. Radiol.* 25, 34, 1996.
5. Menegola E. et al.: Comparative study of sodium valproate-induced skeletal malformations using single or double staining methods. *Reprod. Toxicol.*, 16, 815, 2002.
6. Michalska A. et al.: Optimisation of conditions of visualisation of dental crowns in dental radiography. *Annales UMCS sectio D*, vol. 57, 106, 2002.
7. Mol A., van der Stelt P.F.: Application of computer-aided image interpretation to the diagnosis of periapical bone lesions. *Dentomaxillofac Radiol.*, 21, 190, 1992.
8. Różyło-Kalinowska I. et al.: Badania radiodensytometryczne w ocenie korzeni zębów objętych zmianami zapalnymi okołowierzchołkowymi. *Czas. Stomat.*, LV, 688, 2002.
9. Stamatakis H.C. et al.: Physical properties of photostimulable phosphor system for intra-oral radiography. *Dentomaxillofac. Radiol.*, 29, 28, 2000.
10. Van der Stelt P.F.: Computer assisted interpretation in radiographic diagnosis. *Dent. Clin. North. Am.*, 37, 683, 1993.
11. Versteeg C.H. et al.: Effects of calibration and automatic grayscale adjustment on detectability of simulated bone lesions using a storage phosphor system. *Dentomaxillofac Radiol.*, 27, 240, 1998.

#### SUMMARY

Digital radiography software enables image manipulation and reformatting, thus allowing precise diagnosis and measurements even in cases when exposure parameters are suboptimum and visualized structures are faintly radiopaque. The aim of the paper is evaluation of digital radiography software options in optimization of analysis of skeletal ossification in rats. Wistar rat pups at the age 0 to 22 days of postnatal life were radiographed by means of a storage phosphor digital radiography system. In order to optimize viewing conditions as well as density and linear measurements all available image reformatting options and filters of digital

radiography software Digora 2.0 were used and evaluated. Application of digital radiography image enhancement options was found advantageous in optimization and improvement of viewing conditions and it allowed higher accuracy and reproducibility of the measurements. Digital radiography is a novel and precise tool in determination of skeleton ossification and could be used as a supplement to routine staining methods.

#### Optymalizacja analizy stopnia mineralizacji szkieletu kostnego zwierząt laboratoryjnych przy użyciu opcji obrazowania cyfrowego

Oprogramowanie systemów radiografii cyfrowej pozwala na obróbkę obrazu, a tym samym podwyższa czułość diagnostyczną metody i dokładność przeprowadzanych pomiarów, nawet gdy warunki ekspozycji są suboptymalne, a obrazowane struktury słabo cieniujące. Celem pracy jest ocena opcji oprogramowania systemu radiografii cyfrowej w optymalizacji analizy stopnia mineralizacji szkieletu kostnego zwierząt laboratoryjnych. Zbadano szczury rasy Wistar w wieku od 0 do 22 dni życia przy pomocy systemu radiografii cyfrowej Digora. W celu zoptymalizowania warunków oceny zdjęć, jak również przeprowadzania pomiarów liniowych i pomiarów gęstości, użyto i oceniono wszystkie dostępne funkcje obróbki obrazu oprogramowania Digora 2.0. Zastosowanie cyfrowej obróbki obrazu było korzystne dla optymalizacji i poprawy oceny zdjęć rentgenowskich, jak również pozwoliło na zwiększenie dokładności i powtarzalności przeprowadzanych pomiarów. Radiografia cyfrowa jest nowym i precyzyjnym narzędziem w określaniu stopnia mineralizacji szkieletu kostnego i może być używana jako uzupełniająca w stosunku do rutynowych metod barwienia szkieletu zwierząt laboratoryjnych.